

FEATHER RIVER HOSPITAL

5974 Pentz Road
Paradise, CA 95969
Telephone: 530 877-9361

History and Physical

Patient: JANE APATIENT
Birthdate: May 22, 1949
Examination Date: July 05, 2007
Admitting Physician: Lyle B. Hunt, M.D.
Requesting Physician: Richard Thorp, M.D.
cc: Ronald Ainsworth, M.D.

CHIEF COMPLAINT: Abnormal mammogram on the left

HISTORY OF PRESENT ILLNESS: The patient is a 58 year old female seen for evaluation of an abnormal mammogram on the left. She is seen at the request of Dr. Richard Thorp. She had a routine mammogram and was found to have a mass in the central left breast. She does not perform self breast exams.

GAIL MODEL BREAST CANCER RISK ASSESSMENT: Race = Non Black. Age at Menarche = 14 or older. Number of first-degree relatives with breast cancer = 0. Age at FIRST live birth = 20 years of age. Number of breast biopsies = 1. Atypical hyperplasia on biopsy = At least 1 biopsy and NO atypical hyperplasia found in any biopsy specimen. (The patient is CURRENTLY receiving Hormone Replacement Therapy.) Projected 5 year risk of Invasive Breast Cancer: 1.3% (5 year risk 1.67% is normal).

PAST SURGICAL HISTORY: Hysterectomy and partial oophorectomy 1988. Hammer toe right foot 1978.

PAST MEDICAL HISTORY: Chest pain history, on cardiac medications. Myocardial infarction age 50, stable since. Shortness of breath. Thrombophlebitis [V12.52], of the right leg 9/2003. Diabetes [250.00], currently not taking Insulin [250.00].

REVIEW OF SYSTEMS: ·**Constitutional Symptoms:** Denies change, severe headaches, dizzy spells, fatigue, weakness, marked weight change, night sweats, persistent fever, sensitivity to heat and sensitivity to cold. ·**Cardiovascular:** ·**positive for palpitations and myocardial infarction.** Denies change, angina, atria fibrillation, bradycardia, claudication, rheumatic fever, congestive heart failure, PAC's, PVC's, stroke and thrombophlebitis. ·**Gastrointestinal:** Denies change, constipation, diarrhea, difficult swallowing, gallstones, heartburn, hemorrhoids, hiatal hernia, anorexia, nausea, vomiting, hemoptysis and weight loss. ·**Endocrine:** ·**positive for diabetes.** Denies change, Thyroid disease, goiter and thyroid replacement.

MEDICATIONS: Imdur 60 mg 1 by mouth every day. Lescol 40 mg 1 by mouth every night. Premarin 0.625 mg 1 by mouth every day (M-F). ASA 81 mg 1 by mouth every day.

ALLERGIES: The patient is allergic to Codeine. Tolerates Vicodin.

SOCIAL HISTORY: The patient denies drinking. The patient denies smoking.

FAMILY HISTORY: Father died of abdominal cancer, heart disease, and stroke. Mother died of stroke, colon cancer and diabetes. Son living with hypertension. Daughter living with history of lung cancer and breast tumor. Daughter living with diabetes, Hashimotos.

TRANSFUSION: Options of banked blood, donor designated blood and autologous blood transfusions discussed. Patient agrees to accept banked blood in an emergency situation.

CHEST: Lungs are clear to auscultation and percussion.

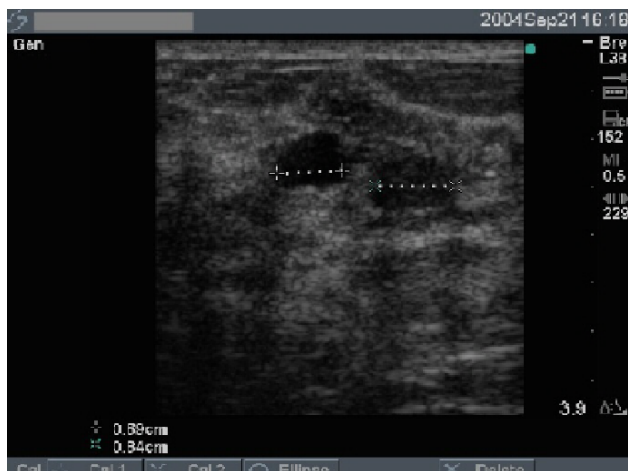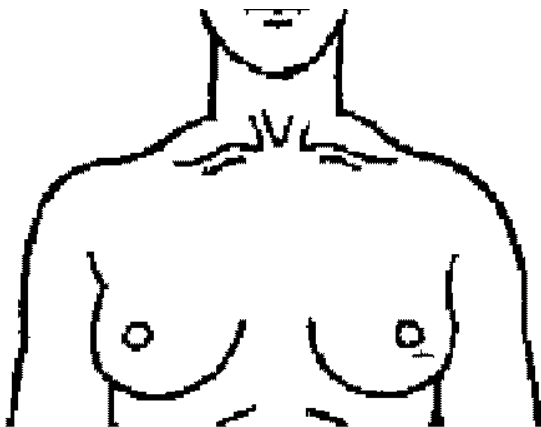
HEART: Regular rate and rhythm, without murmurs, clicks or rubs.

BREAST: RIGHT BREAST EXAM: negative for masses or tenderness of the breast, axilla or supraclavicular area. LEFT BREAST EXAM: negative for masses or tenderness of the breast, axilla or supraclavicular area. See Ultrasound report.

DATA REVIEW: Mammogram demonstrates two lesion in the central left breast consistent with cysts. Ultrasound in the office demonstrated 2 small cysts in the left central breast.

IMPRESSION: #1. Abnormal mammogram on the left. My ultrasound here in the office suggests this area is most likely two breast cysts [610.0]. #2. History of chest pain, on cardiac medications, myocardial infarction age 50 stable since. #3. Thrombophlebitis [V12.52] of the right leg 9/2003. #4. Diabetes [250.00] currently not taking insulin [250.00].

PLAN: Proceed with needle drainage under ultrasound guidance.



Lyle B. Hunt M.D.

Digitally Signed/Locked 07/05/2007 12:06

Lyle B. Hunt, M.D.

07/05/2007 12:07 PM/td-emr